

# A guide to the diagnosis and management of hip pain

Philip Stott                      Consultant Orthopaedic Surgeon.    BSUH

## Learning Objectives

Feel confident to take histories from patients with hip problems

Know when to refer patients for imaging of the hip

Understand common hip conditions

Be aware of the local hip pathway within Sussex MSK Partnership (central)

## History

### Pain History

Location

Radiation

Aggravating factors

Time

Night pain

### Where is the pain?

Lateral (flat hand / point)

Buttock

Anterior (C-sign)

Knee

### Specific Hip questions

What aggravates the pain?

Specific movements

Clicking/ Snapping / Popping

Instability

Stiffness (Toenails)

Walking Aids (which hand ?)

Age /Occupation of Patient

Duration of Symptoms

How did the pain start?

Trauma / Previous surgery

Effect on ADL

Family History  
Other Arthropathies

Total Hip Extra Questions  
For loosening  
Pain rising out of a chair  
Thigh pain

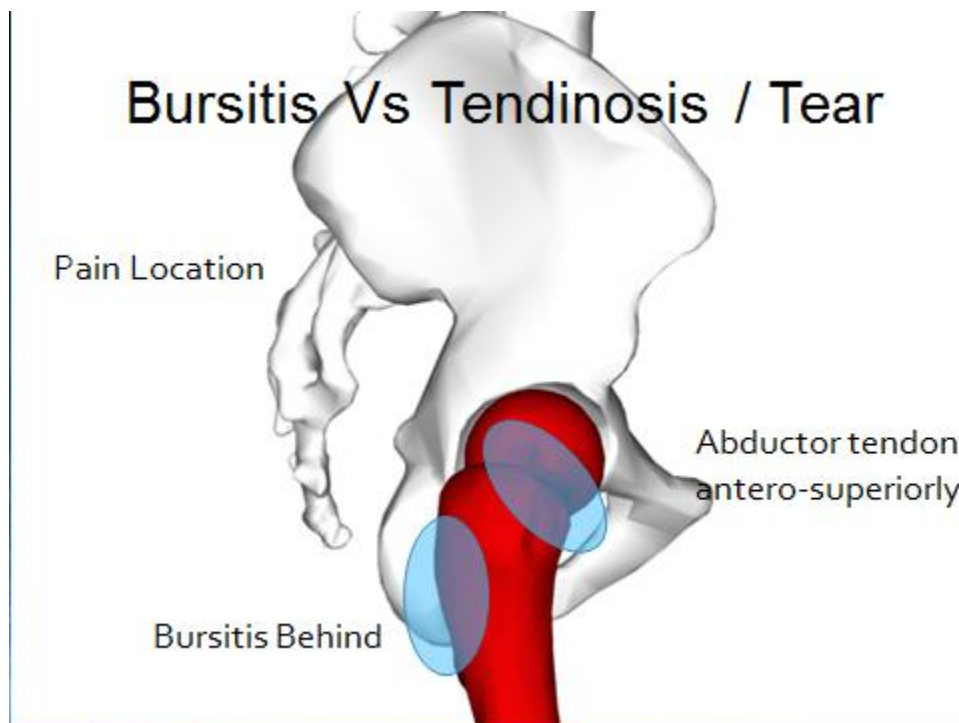
Instability  
Number of dislocations  
How does it dislocate?

Back questions  
Lumbar spine or Buttock Pain  
Numbness / Tingling / Weakness  
(Urinary disturbance)

### Location of pain - Lateral

Top 3

Trochanteric Bursitis (Lateral Hip Pain Syndrome)  
Gluteus Medius Tear  
External Snapping Hip



## Trochanteric Bursitis

Primary = Rare

Secondary to other joint problem, causing abnormal gait / muscle function

Trochanteric Bursitis

Usually a symptom, not a stand alone diagnosis

Examine other joints and spine

Main treatment is correct cause / physio

Only inject in conjunction with physio (max X2)

Refer if still has pain despite good course of physio

## Trochanteric Bursitis - Surgical options

Limited

If cause can be identified - correct cause, e.g. revise hip with abnormal biomechanics

Debride bursa and surgical lengthening of IT band.

Often tendinosis seen at time of surgery

Extensive rehab required

## **Gluteus Medius tear**

Usually affects elderly

Unable to Abduct leg when lying on side

Trendelenberg sign

### **Acute Tear**

Usually sudden onset severe lateral hip pain and limp (stumble or trauma)

Pain settles after a few weeks, but limp does not

Refer urgently

Best surgical results within 6 weeks of tear

### **Chronic Tear**

Trendelenberg gait

Trial of physio

Refer – assess for surgery

Management (Rotator Cuff Tear of Hip)

Investigation : No primary care investigation possible

MRI can be difficult to interpret

### **External Snapping Hip**

Usually Young Females (12 to 30)

Party Trick

Can be painful

Tough rope like Ilio-tibial band rubs over greater trochanter

History

Patient sometimes describes it as a dislocation

Snapping sound

+/- pain

Examination

Ask patient to demonstrate

Hand over trochanter and rotate leg – feel clunk

Investigation

None needed

Management

Physio – TFL stretches

Avoid party trick

Last resort

Refer for surgery – Usually successful but scar

ITB lengthening

### **Lateral Hip Summary**

Patient describes pain with a flat hand or points laterally

Most conditions are managed by physio

Injections have little benefit as a stand alone management

Watch out for Acute Muscle tears

### **Buttock Pain**

Usually Spinal Cause

Very rarely hip is a cause

Piriformis syndrome (Part of Deep Gluteal syndrome)

Posterior hip impingement.

## **Piriformis syndrome**

Is a label for sciatica without obvious spinal cause

Probably double crush syndrome

17% of Sciatic nerves pass through piriformis rather than under it

Piriformis syndrome

Other causes;

Inactive gluteal muscles - people spending too much time with hips flexed

Overactive short hip flexors

Patient uses gluteal synergists – hamstrings, adductor magnus and piriformis to extend hip.

Piriformis syndrome

Management

Avoidance of contributing factors

Short course anti-inflammatories

Physiotherapy – core stability, flexor / lateral stretches and glut work

## **Anterior Groin Pain**

Causes of anterior groin pain

Hip

Intra-capsular (ie joint)

Extra-capsular (muscles and tendons)

Spine (L5 /S1 radiculopathy)

Herniae

Vascular

Gynaecological

C-Sign

Usually Specific to hip problem

Patient makes a 'C' shape with thumb and index finger, encompassing hip

Intra-capsular Pathology

Abnormal Shaped Hip

Femoro Acetabular Impingement (FAI)

Degenerate Hip

Femoro Acetabular Impingement (FAI)

Cartilage damage (Arthropathy)

Abnormal Bone

Avascular Necrosis

Impending Pathological Fracture

# **Femoro – Acetabular Impingement**

Abnormal contact between femoral neck and acetabular structures

2 sorts

CAM

Pincer

Femoro-Acetabular Impingement - Cam

Surgery - Open

Hip Arthroscopy

Femoro-Acetabular Impingement - Pincer

What is the pathogenesis?

Cam type (commoner)

Male > Female

Overuse (>90% of Premiership players)

Genetic component

Externally rotated hips

Pincer Type

Female >> Male

Genetic

Idiopathic

Outcomes of Arthroscopy

Will it stop OA? – probably not – reduces rate of arthritis

What does it do?

Reduces symptoms

Allows sports

Probably reduces time to replacement

Type of patient

Usually sporty

Any age / either sex

How does the patient present?

Symptoms

Groin pain – movement related (not constant)

Catching

Feelings of instability

Occasionally popping or snapping sound

Often diagnosed as muscle sprain

How does the patient present?

Signs

Impingement test – Flex hip and internally rotate in increasing degrees of adduction  
-recreates pain

Management

Modify behaviour (stop breast – stroke, road running, rugby, golf)

Physio – Centralises hip. Does not work for all

Referral (specialist Xrays/ scans required)

## **Arthritis**

Pain

Stiffness

Night pain

Lack of function

Arthritis

Early management

Analgesics (WHO ladder)

Advice – lifestyle, exercise

Physio

Viscosupplementation

Shoewear

What investigations should be ordered?

X-ray – standard AP (GP)

MRI (arthrogram)

3D CT

When to refer with OA?

Each patient different

When it stops them doing what they want to do

Night pain

Not stiffness

Patient reassurance

## **Avascular Necrosis**

Causes

Alcoholism

History of steroids

Post trauma

Caisson disease (decompression sickness)  
Vascular compression,  
Hypertension  
Vasculitis  
Arterial embolism and thrombosis,  
Radiation damage  
Bisphosphonates  
Sickle cell anaemia,  
Gaucher's Disease  
Deep diving  
Idiopathic

Brighton Patients – anti-HIV medication

#### Presentation

Pain  
Usually Severe  
Night Pain  
Limp  
Painkillers no real help

#### Examination

May have full range of motion  
Pain worse at extremes of motion  
Pronounced limp

#### **Extracapsular Causes of Hip Pain**

Muscle tears / sprains (inc Gilmore's Groin)

Tendinopathies  
Ilio-psoas syndrome (Internal Snapping Hip)  
Stress Fractures in Runners  
Muscle Tears / Sprains  
Usually sport related  
If localises pain above inguinal ligament = hernia  
Management  
Rest / NSAIDS  
Refer to physio if not settling  
No investigation needed initially  
If still not settling refer to hip clinic

#### **Tendinopathies**

Usually affect athletes  
Repetitive motion

Commonest = Ilio-psoas syndrome (Internal Snapping Hip)



Ilio-psoas tendon snaps over hip joint  
Tender anteriorly over hip  
Normal internal rotation  
Refer to physio – stretches  
If no improvement - refer

### **Summary of anterior groin pain**

Look for other causes  
Impingement sign needs physio as a minimum  
Xray if suspect osteoarthritis  
Refer for THR if night pain or patient not doing what they want to do  
Sprains/strains – if below the inguinal ligament then refer for physio

### **Stress Fractures**

Common 5-30% of athletes  
Most common in tibia / foot

Can occur around pelvis / hip  
Seen in runners

#### Predisposing factors

Female  
Caucasian  
Rapid increase in training program  
Hormonal / nutritional disturbance

#### Types

Pubis / Pubic rami  
Sacrum (usually osteoporotic)  
Femoral neck  
Tension  
Compression

#### Symptoms

Variable  
Can be mild, such as experiencing increasing pain throughout run  
Or more severe – so that patient can not weight bear

#### Stress Fractures - Signs

Difficult and variable  
Tender over bone  
Pain at extremes of rotation of hip  
Antalgic gait

Stress Fractures - Management  
Imaging

Mostly conservative - ? Tension fracture neck of femurs needs operation

Philip Stott  
Consultant Orthopaedic Surgeon  
[philip.stott@bsuh.nhs.uk](mailto:philip.stott@bsuh.nhs.uk)  
[philip.stott@springgroup.org](mailto:philip.stott@springgroup.org)