

Hand and Wrist **Injections in** **Primary Care**

Jim Rehill
Primary Care Lead
Sussex MSK Partnership Central
11th April 2018

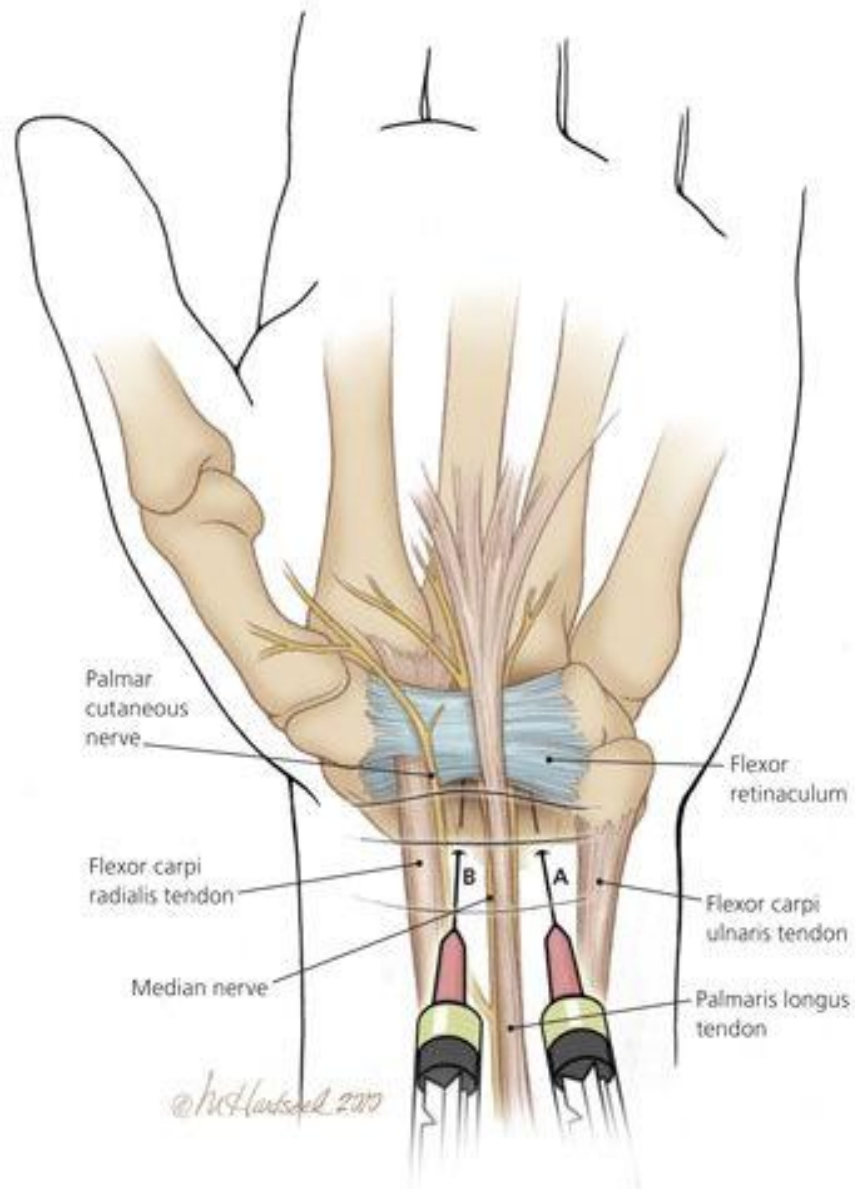
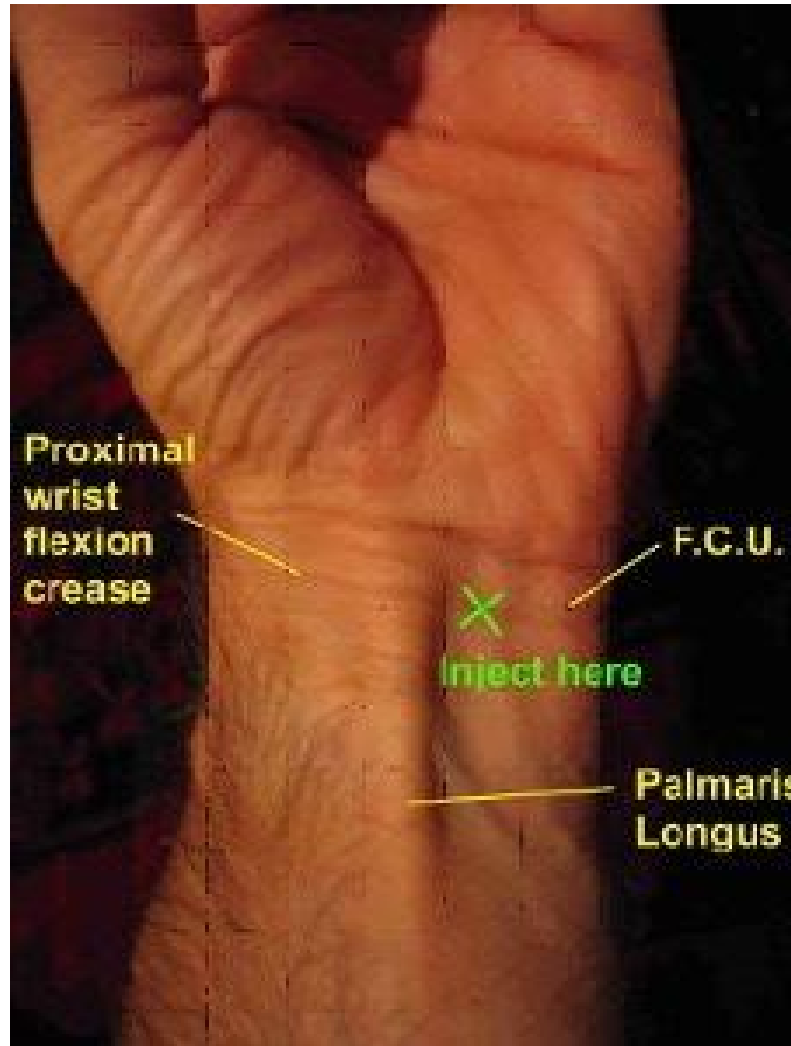
- Carpal Tunnel Syndrome
- De Quervain's Tenosynovitis
- Trigger finger
- 1st Carpometacarpal Osteoarthritis

General guide

- Depomedrone 10-20mg (or Triamcinolone, Hydrocortisone)
- Orange needle (can use Blue for CTS)
- Small volumes: 0.5-1ml
- LA not required for CTS injection
- 1% lignocaine lasts 1-2 hours

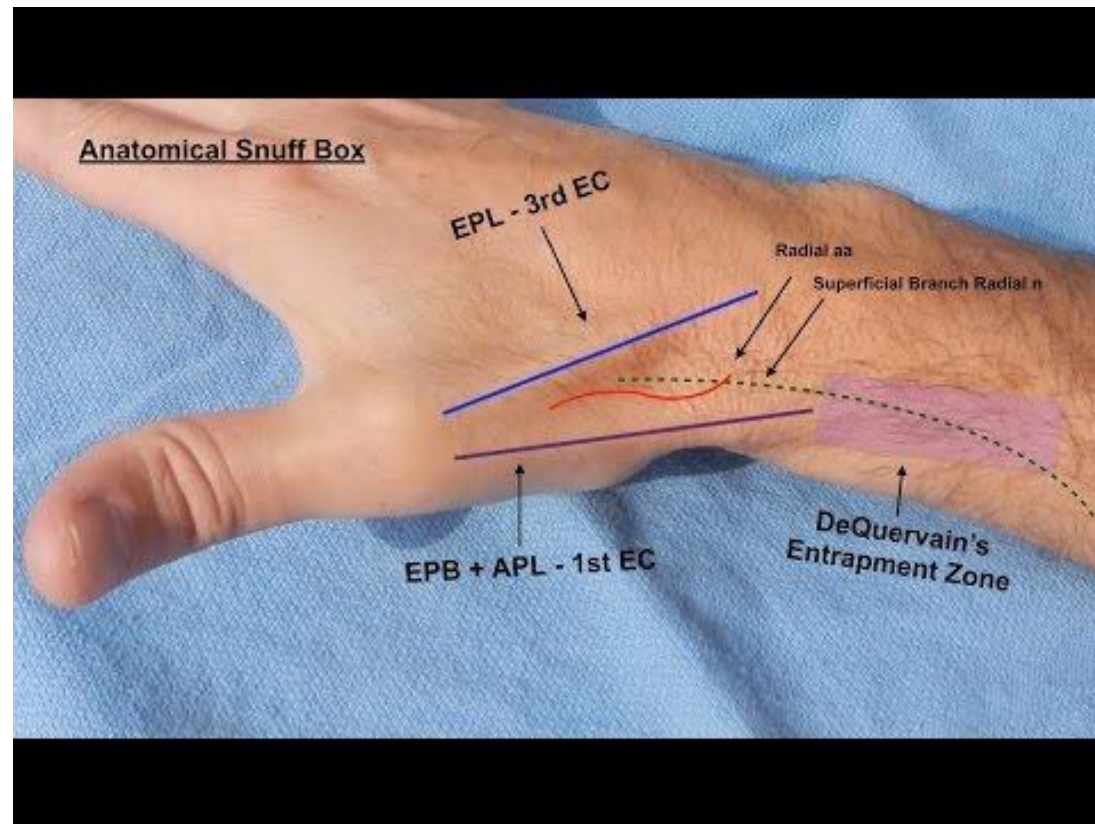
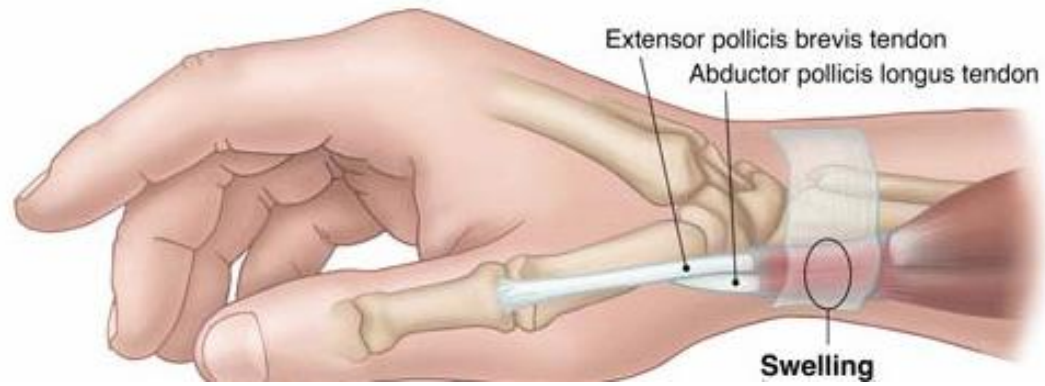
Carpal Tunnel Syndrome

- elevated carpal tunnel pressure
- assoc with: Hypothyroidism, RA, T2DM, Pregnancy, previous wrist frax
- pain and/or paraesthesia radial 3 1/2 digits (Diff Dx C7 radiculopathy)
- often worse nocte and relieved by shaking hands
- gripping problematic
- Tinnels/Phalen/CT compression/hand elevation tests all appx 70-80% sensitive and specific
- 1/3 get better with splints
- if constant tingling/wasting refer for decompression



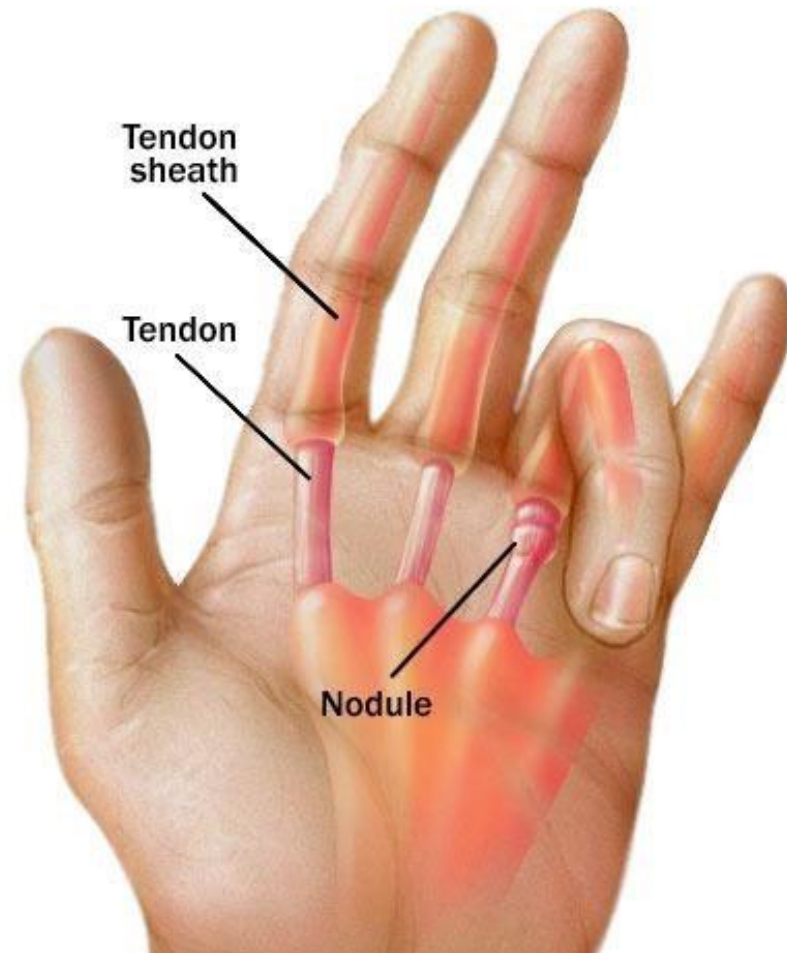
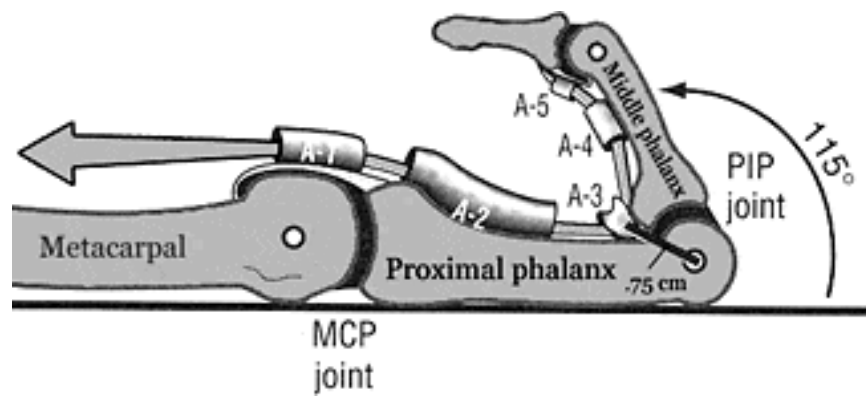
De Quervains Tenosynovitis

- stenosing tendinosis of 1st dorsal compartment, 'washer-woman's thumb'
- fibrosis of tenosynovium of APL and EPB
- RSI type injury (though term no longer used) e.g new mothers
- swelling and crepitus sometimes seen
- Finkelstein's test / Hitchhiker's sign



Trigger Finger

- nodule on flexor tendon of affected digit as it passes under A1 pulley at base of finger exacerbated by synovitis
- assoc with RA, T2DM, F>M
- Often palpable nodule at MCP jt
- not all lock, sometimes there is just a painful nodule
- nearly 50% patients reporting long term success after single injection
- if finger stuck in flexion - urgent referral MSK (this will be directed straight to hand surgeons)



1st CMC Osteoarthritis

- assoc with generalised OA, F>M
- pain at base of thumb, loss of grip strength
- Differential: De Quervains
- squaring of base of thumb
- maybe thenar wasting

